

Case Report

Dynamic Lumbar Spinal Stenosis : The Usefulness of Axial Loaded MRI in Preoperative Evaluation

Kyung-Chul Choi, M.D.,¹ Jin-Sung Kim, M.D.,¹ Byungjoo Jung, M.D.,Ph.D.,² Sang-Ho Lee, M.D., Ph.D.¹

Department of Neurosurgery,¹ Wooridul Spine Hospital, Seoul, Korea

Department of Neurosurgery,² Wooridul Spine Hospital, Shanghai, China

Two cases of dynamic lumbar spinal stenosis were identified by the authors using axial loaded magnetic resonance image (MRI). In both cases, the patients presented with neurogenic claudication but MRI in decubency showed no definite pathologic condition associated with their symptoms. In contrast, axial loaded MRI demonstrated constrictive spinal stenosis and a significantly decreased dural sac caused by epidural fat buckling and thickening of the ligamentum flavum in both cases. In the second case, a more prominent disc protrusion was also demonstrated compared with decumbent MRI. After decompressive surgery, both patients had satisfactory outcomes. Axial loaded MRI can therefore give decisive information in dynamic spinal disorders by allowing simulation of an upright position.

KEY WORDS : Axial loaded MRI · Dynamic lumbar spinal stenosis · Neurogenic claudication.

INTRODUCTION

In spinal stenosis, dynamic changes of the spine can affect the severity of the clinical symptoms. Typically, the pain is worsened by an upright posture that occurs with sitting, standing, or walking, as this contributes to a decrease in the dimension of the spinal canal. Forward flexion, on the other hand, enlarges the spinal canal and relieves the clinical symptoms.

Currently, magnetic resonance image (MRI) is a useful diagnostic tool for spinal stenosis. However, conventional MRI has a limitation in that acquisition of the scan image is normally performed with the patient in a decumbent position. Weight bearing is not taken into consideration, although this is an important factor that contributes to adjustments in the intervertebral foramen and in dynamic spinal changes⁽¹⁾. In the present paper, an axial loaded device was developed to simulate the upright position, which influences the structures of the spinal canal and

changes the size of the dural sac^(3,14). We introduce two cases of occult lumbar spinal stenosis with no obvious MRI features that were both successfully identified with axial loaded MRI as a dynamic lumbar spinal stenosis.

CASE REPORT

Case 1

A 65-year-old male presented with a 3-year history of pain of insidious onset in both legs. The pain involved buttocks, thighs, and legs and was exacerbated by standing, sitting, and walking. The pain was dramatically relieved by assuming a supine position. The patient gradually presented the pain upon walking shorter and shorter distances. His leg pain considerably affected his daily living activities. He had undergone physical therapy for one year. He also underwent epidural blocks and lumbar nerve root blocks several times in pain clinics. The patient even underwent bilateral release of the tarsal tunnel in an orthopedic clinic 3 months previously. However, the pain was not relieved at all. At presentation, the patient was unable to walk independently more than 50 m. The patient had had electromyography (EMG), Doppler ultrasonography (USG) and computed tomographic (CT) angiography performed in another hospital. These checks had revealed no definite

• Received : June 17, 2009 • Revised : July 7, 2009
• Accepted : August 17, 2009
• Address for reprints : Jin-Sung Kim, M.D.
Department of Neurosurgery, Wooridul Spine Hospital, 47-4
Cheongdam-dong, Gangnam-gu, Seoul 135-100, Korea
Tel : +82-2-513-8151, Fax : +82-2-513-8146
E-mail : mddavidk@dreamwiz.com

abnormality. Conventional MRI in decumbency also demonstrated no obvious features of spinal canal stenosis, hypertrophy of the ligamentum flavum, or disc protrusion. However, his clinical symptoms strongly suggested spinal stenosis. The patient was checked with axial loaded MRI, using a previously described technique¹⁴. The patient was placed in the supine position with a cushion behind the lumbar spine and with hips and knees extended and feet against a footplate on the compression device and harness (DynaWell, DynaMed AB, Stockholm, Sweden) (Fig. 1). Fifty percent of his body weight was distributed equally to both legs. His body weight was 80 kg. We applied 20 kg of axial load to each leg. After 10 minutes of loading, sagittal and axial T2-weighted sequences were performed. It took 6 minutes to perform a complete study. The pain, which was similar to the ordinary pain he experienced on standing, occurred during the scanning. Sagittal images showed dural sac compression caused by buckling of epidural fat and

thickening of the ligamentum flavum at the level of L3-5. Axial images demonstrated a concentric restriction of the spinal canal due to thickening of a dorsal fat pad and the ligamentum flavum at level of L3-4 and L4-5 (Fig. 2). Compared to MRI in decumbency, the cross sectional area of the dural sac significantly decreased from 135.9 mm² and 146.6 mm² to 99.3 mm² and 103.1 mm² at level of L3-4 and L4-5, respectively.

The patient underwent decompressive unilateral laminectomy and bilateral ligamentum flavectomy of L3-5. Visual Analogue Scale (VAS) for leg pain and Oswestry Disability Index (ODI) score were improved from 7 and 58% preoperatively to 2 and 14% at the 3-month follow-up.

Case 2

A 67-year-old male presented with a 1-year neurogenic claudication. The pain was exacerbated by standing and especially by walking. If he walked beyond 10 minutes, numbness in both legs was developed. The pain was relieved by squatting and by decumbency. Pulsation of both dorsalis pedis arteries were felt well. The patient had no medical problems except hypertension. EMG of the legs revealed no abnormality and CT angiography revealed no stenotic lesions of vessel for the lower extremities. He had taken medications and undergone physical therapy for 6 months. He still complained of the pain and could not walk for more than 5 minutes. Although the patient had undergone a nerve block in our clinic, the pain was not relieved. MRI in decumbency showed no obvious lesion that could be associated with his symptoms. The patient was checked with axial loaded MRI. A T2-sagittal image demonstrated that the thecal sac was compressed posteriorly due to protrusion of the dorsal fat pad. A T2-axial image showed that the size of the thecal sac was significantly

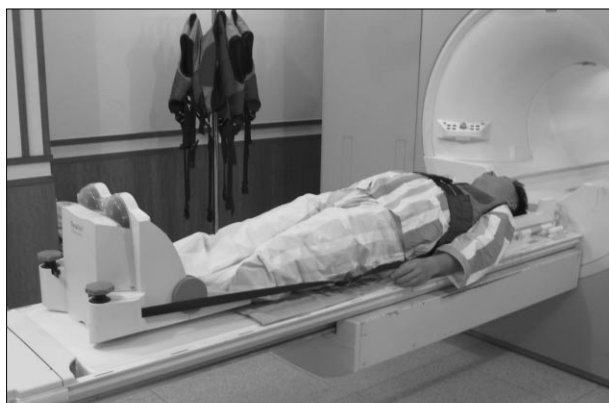

Fig. 1. Patient in axial loading with the device (DynaWell, DynaMed AB, Stockholm, Sweden), which consists of a harness and a foot-operated device connected by straps. By appropriately tightening the straps, the amount of axial load can be controlled.

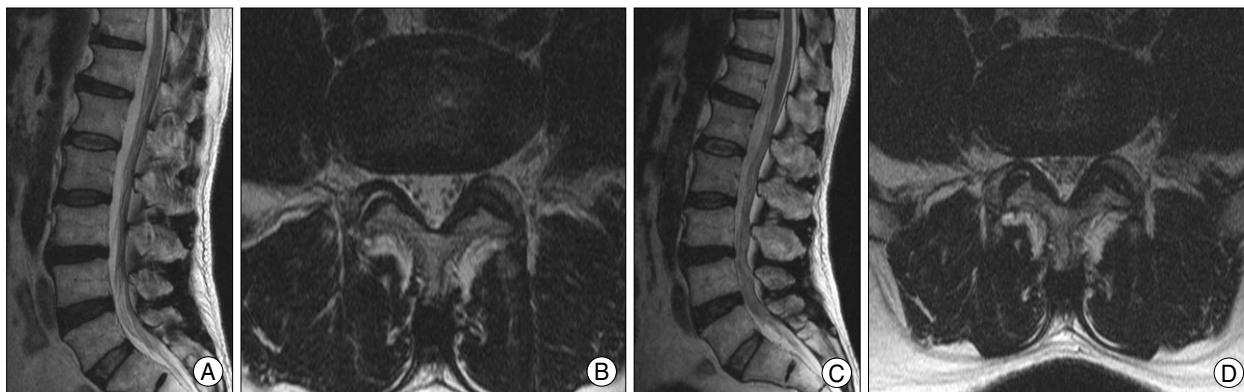


Fig. 2. A 65-year-old man with neurogenic claudication (case 1). A : Sagittal T2-weighted magnetic resonance image indicating normal spinal alignment with minimal degenerative changes. B : Axial T2-weighted image showing no obvious lesion of spinal stenosis at L4-5. C : Axial loaded mid-sagittal T2-weighted image showing central canal stenosis by indentation of a dorsal fat pad and thickening of the ligamentum flavum. D : Axial loaded T2-weighted axial image showing constriction of the dural sac with thickening of the ligamentum flavum at L4-5. The size of the dural sac significantly decreased from 146.6 mm² during decumbency to 103.1 mm² during axial loading.

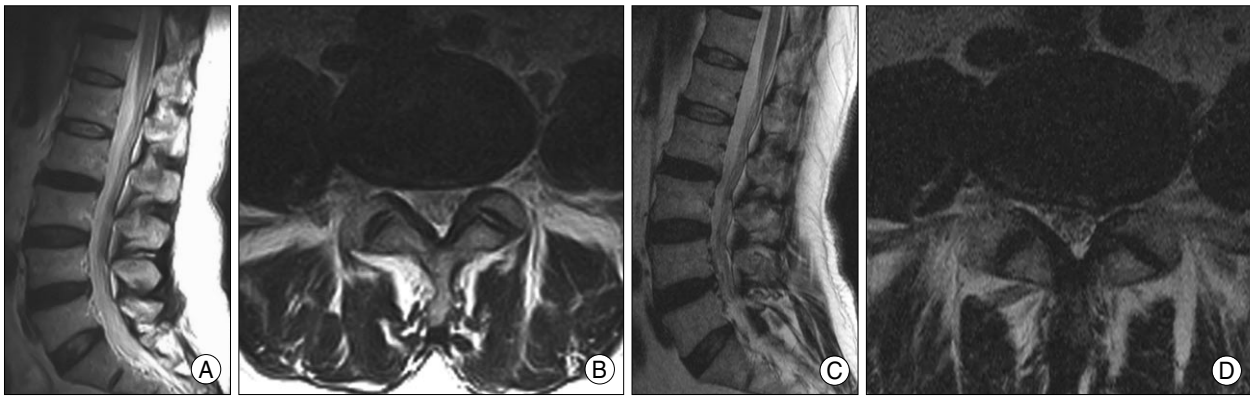


Fig. 3. A 67-year-old man with 1-year neurogenic claudication (case 2). A : T2-weighted sagittal image demonstrating no obvious central canal stenosis. B : T2-weighted axial image demonstrating mild spinal stenosis with hypertrophy of the ligamentum flavum at L4-5. C : Axial loaded T2-weighted image demonstrating more prominent central canal stenosis by indentation of posterior elements at L2-5. D : Axial loaded axial image demonstrating that development of paracentral disc protrusion, thickening of the ligamentum flavum and protrusion of the dorsal fat pad causing central canal stenosis at L4-5. The size of the dural sac decreased from 110.2 mm² to 68.7 mm²

smaller than that in decumbency at the level of L2-3, 3-4, and 4-5 (Fig. 3). Compared to MRI in decumbency, the cross sectional area of the dural sac significantly decreased from 138.1 mm², 121.9 mm² and 110.2 mm² to 104.8 mm², 77.6 mm² and 68.7 mm² at the level of L2-3, L3-4 and L4-5, respectively. Axial loaded MRI demonstrated a dorsal protrusion of the dorsal fat pad and thickening of ligamentum flavum. Especially, prominent disc protrusion of the L4-5 was noted, which could not be found in decumbency. The patient underwent left laminectomy and bilateral ligamentum flavectomy of the L2-5. Preoperative VAS and ODI score were improved from 8 and 52% to 3 and 16% at the 3-month follow-up.

DISCUSSION

Human posture is continuously subject to the effects of gravity in positions other than that of recumbent. In posture-dependent degenerative spinal disease, and especially in spinal stenosis, weight-bearing dependent postures contribute to the development or aggravation of the clinical symptoms due to changes in the morphology of the spine. Physiologic axial loading increases redundancy of the discal, ligamentous, and meningeal tissues of the spine and results in increased degrees of central canal and lateral recess spinal stenosis^{1,6}.

Several authors have reported that axial loading influences spinal dynamics and morphologic changes during MRI and CT^{9,10,13,14}. With MRI, changed structures of the spine are found on axial loading, although upright MRI would be a theoretically ideal diagnostic tool to simulate the spinal column and its contents under physiological conditions^{7,8}. In our cases, the patients were clinically suspected of spinal stenosis but had no obvious MRI findings in decumbency.

At first, other diagnoses should be ruled out for these patients, such as metabolic neuropathy, peripheral nerve entrapment syndrome, peripheral neuropathy, and vascular claudication, prior to considering neurogenic claudication. In our patients, EMG, Doppler USG, and CT angiography for the lower extremity revealed no abnormality. The patient in the first case even underwent tarsal tunnel release at other orthopedic clinic. Axial loaded MRI demonstrated concentric restriction of the spinal canal compared to MRI in decumbency.

Axial loading affects structures within the spinal canal, as it contributes to protrusion of epidural fat pads, thickening of the ligamentum flavum, and prominent disc protrusion. Significantly decreased cross sectional dural sac area was also seen in comparison to MRI in decumbency. Danielson et al.³ studied the effect of axial loading on the lumbar spine in suspected lumbar spinal stenosis. They reported that axial loading significantly decreased size of the dural sac. In 76% patients with suspected spinal stenosis, a significant difference in the size of the dural sac was found.

In axial loaded MRI, a more prominent indentation of the dorsal fat pad, thickening of the ligamentum flavum, or a more pronounced disc protrusion are found. In asymptomatic individuals, axial loaded MRI less frequently (56%) resulted in decreased the size of the dural sac than did MRI in decumbency². Hiwatashi et al.⁵ suggested that axial loaded MRI can influence the treatment decisions for symptomatic spinal stenosis. These authors showed that treatment decisions had been changed in 10 out of 20 patients who had a narrowing of the spinal canal detected with axial loaded MRI. Furthermore, treatment decisions of 5 patients changed from conservative management to decompressive surgery.

In our cases, the authors performed decompression of

multi-levels, which were found to be compressed using axial loaded MRI and this resulted in satisfactory outcomes. Some authors have suggested that neurogenic claudication is associated with at least two levels of stenosis¹². Hamanishi et al.⁴ also supported this hypothesis, as they reported that a cross-sectional area of below 100 mm² at more than two levels was highly associated with the presence of neurogenic claudication.

Although some patients have difficulty in undergoing axial loaded MRI as it provokes their pain, the pain is typically consistent with their usual pain. This finding may also be a clue for diagnosis of dynamic lumbar spinal stenosis. Axial loaded MRI may provide decisive radiologic and clinical information in these patients with occult spinal stenosis, although it can not reflect tension of the muscles and ligaments in the upright position.

CONCLUSION

Axial loaded MRI may contribute to overcoming a limitation of MRI in decumbency, which can overlook dynamic spinal disorders such as dynamic lumbar spinal stenosis.

• Acknowledgements

This study was supported by a grant from the Woordul Spine Foundation.

References

1. Alyas F, Connell D, Saifuddin A : Upright positional MRI of the lumbar spine. *Clin Radiol* 63 : 1035-1048, 2008
2. Danielson B, Willén J : Axially loaded magnetic resonance image of the lumbar spine in asymptomatic individuals. *Spine (Phila Pa 1976)* 26 : 2601-2606, 2001
3. Danielson BI, Willén J, Gaultitz A, Niklason T, Hansson TH : Axial loading of the spine during CT and MR in patients with suspected lumbar spinal stenosis. *Acta Radiol* 39 : 604-611, 1998
4. Hamanishi C, Matukura N, Fujita M, Tomihara M, Tanaka S : Cross-sectional area of the stenotic lumbar dural tube measured from the transverse views of magnetic resonance imaging. *J Spinal Disord* 7 : 388-393, 1994
5. Hiwatashi A, Danielson B, Moritani T, Bakos RS, Rodenhause TG, Pilcher WH, et al. : Axial loading during MR imaging can influence treatment decision for symptomatic spinal stenosis. *AJNR Am J Neuroradiol* 25 : 170-174, 2004
6. Jenkins JR, Dworkin JS, Damadian RV : Upright, weight-bearing, dynamic-kinetic MRI of the spine : initial results. *Eur Radiol* 15 : 1815-1825, 2005
7. Kimura S, Steinbach GC, Watenpaugh DE, Hargens AR : Lumbar spine disc height and curvature responses to an axial load generated by a compression device compatible with magnetic resonance imaging. *Spine (Phila Pa 1976)* 26 : 2596-2600, 2001
8. Madsen R, Jensen TS, Pope M, Sørensen JS, Bendix T : The effect of body position and axial load on spinal canal morphology : an MRI study of central spinal stenosis. *Spine (Phila Pa 1976)* 33 : 61-67, 2008
9. Meakin JR, Smith FW, Gilbert FJ, Aspden RM : The effect of axial load on the sagittal plane curvature of the upright human spine in vivo. *J Biomech* 41 : 2850-2854, 2008
10. O'Connell GD, Johannessen W, Vresilovic EJ, Elliott DM : Human internal disc strains in axial compression measured noninvasively using magnetic resonance imaging. *Spine (Phila Pa 1976)* 32 : 2860-2868, 2007
11. Panjabi MM, Oxland TR, Yamamoto I, Crisco JJ : Mechanical behavior of the human lumbar and lumbosacral spine as shown by three-dimensional load-displacement curves. *J Bone Joint Surg Am* 76 : 413-424, 1994
12. Porter RW, Ward D : Cauda equina dysfunction. The significance of two-level pathology. *Spine (Phila Pa 1976)* 17 : 9-15, 1992
13. Willén J, Danielson B : The diagnostic effect from axial loading of the lumbar spine during computed tomography and magnetic resonance imaging in patients with degenerative disorders. *Spine (Phila Pa 1976)* 26 : 2607-2614, 2001
14. Willén J, Danielson B, Gaultitz A, Niklason T, Schönström N, Hansson T : Dynamic effects on the lumbar spinal canal : axially loaded CT-myelography and MRI in patients with sciatica and/or neurogenic claudication. *Spine (Phila Pa 1976)* 22 : 2968-2976, 1997