

The Diagnostic Effect From Axial Loading of the Lumbar Spine During Computed Tomography and Magnetic Resonance Imaging in Patients With Degenerative Disorders

Jan Willén, MD, PhD,* and Barbro Danielson, MD, PhD†

Study Design. Patients with low back pain, sciatica, and neurogenic claudication were observed during computed tomographic myelography or magnetic resonance imaging in psoas-relaxed position and axially compressed supine position of the lumbar spine.

Objective. To estimate the clinical value of axially loaded imaging in patients with degenerative disorders of the lumbar spine.

Summary of Background Data. Computed tomography and magnetic resonance imaging still are performed with the lumbar spine in a supine relaxed position, which results in unloading of the spine and enlargement of the canal.

Methods. A device for axial loading of the lumbar spine in computed tomography and magnetic resonance imaging was used. Altogether, 172 patients were examined in psoas-relaxed position and axially compressed supine position of the lumbar spine: 50 patients with computed tomographic myelography and 122 patients with magnetic resonance imaging. If a significant decrease ($>15 \text{ mm}^2$) in the dural sac cross-sectional area to values smaller than 75 mm^2 (the borderline value for stenosis) was found during examination in axial loading, or if a suspected disc herniation, narrow lateral recess, narrow intervertebral foramen, or intraspinal synovial cyst changed to being obvious at the axial loading examination, this was regarded as additional information important for the treatment.

Results. Additional valuable information was found in 50 of 172 patients (29%) during examination in axial loading. In the different diagnostic groups, additional valuable information was found in 69% of the patients with neurogenic claudication, in 14% of the patients with sciatica, and in 0% of the patients with low back pain. The percentage of additional valuable information increased to 50% in the patients with sciatica, if recommended inclusion criteria for examinations in axial loading were used. A narrowing of the lateral recess causing compression of the nerve root was found at 42 levels in 35 patients at axial loading.

Conclusion. According to the study results, axially loaded imaging adds frequent additional valuable information, as compared with conventional imaging methods, especially in patients with neurogenic claudication,

but also in patients with sciatica if defined inclusion criteria are used. [Key words: axially loaded, CT, lumbar spine, MRI, neurogenic claudication, sciatica] **Spine 2001; 26:2607–2614**

Myelographic examination including flexion and extension of the lumbar spine in a standing position has long been used as a diagnostic tool in patients with suspected encroachment into the spinal canal.^{1,2,22,23} It is well documented that a narrowing of the spinal canal is provoked in axial loading, especially when it is combined with extension of the spine.^{10,14,20–23} Since the advent of computed tomography (CT) scanning, and especially with the introduction of magnetic resonance imaging (MRI), these noninvasive techniques have replaced myelography in most cases, mainly because of their superior capabilities for analyzing the content of the spinal canal. However, CT scanning as well as MRI have been performed with the lumbar spine in a supine relaxed position, which results in unloading of the spine and enlargement of the canal. Encroachments into the canal might thus remain undetected.

In patients with suspected spinal stenosis, axial loading of the lumbar spine in extension (ACE) during CT and MRI examinations recently has showed pathologic features not detected in the conventional, unloaded examination position (psoas-relaxed position [PRP]). In 29 of 84 patients with sciatica or neurogenic claudication, the load provocation disclosed relative or absolute stenosis at 40 disc sites.^{4,21,28} A common finding in ACE was a bulging disc, a thickening of the ligamentum flavum, a changed pattern of the dorsal fat pad causing a deformation of the dural sac, and free nerve roots at the level of the disc or the lateral recess.

According to these results, there is a considerable risk of failing to detect an essential narrowing of the spinal canal if only the relaxed position is used during the examination. The ACE examination is recommended when the cross-sectional area of the dural sac is smaller than 130 mm^2 , or when there is a suspected narrow lateral recess, with or without deformation of the anterolateral part of the dural sac or suspected pressure on the nerve roots in the conventional PRP examination.^{4,21,28}

The purpose of the current study was to evaluate the impact of axially loaded CT scanning and MRI in patients with different lumbar spinal disorders.

From the *Department of Orthopaedics, and the †Department of Radiology, Sahlgrenska University Hospital, Göteborg, Sweden. Supported in part by research grants from the Foundation for the Memory of the Consul Thure Carlsson, Lund, and FoU, Bohuslän County Council, Göteborg, Sweden.
Device status category: 11.
Conflict of interest category: 17.




Figure 1. Patient in a supine position during axial compression (ACE). The device consists of a harness attached to a nonmagnetic compression part by nylon straps, which are tightened to axially load the lumbar spine. By tightening or loosening adjustment knobs on the compression part, the load can be regulated and equally distributed on both legs.

Materials and Methods

A compression device, Dynawell (Figure 1), was used to perform the axially loaded examinations. This device consists of a nonmagnetic compression part and a harness. Worn by the patient, the harness is attached to the compression part using nylon straps, which are tightened to load the lumbar spine axially. During the procedure, the harness is tightened across the lower part of the chest to avoid pressure on the shoulders. It is crucial to control the straps passing the dorsal part of the femoral trochanters to maintain the lumbar lordosis.

In this study, the load chosen was approximately 40% of the subject's body weight, never exceeding 50% to avoid injuries to the patient. This choice of load was based on previous disc pressure measurement findings at L3–L4 in standing subjects reported by Nachemson and Elfström¹¹ and later by Sato et al.¹⁷

By tightening or loosening adjustment knobs on the compression part, the load was regulated and equally distributed on both legs. The device was compatible with CT and MR scanners, enabling examination of the patients in a supine position with straightened legs, simulating the axial load on the lumbar spine in an upright position (*i.e.*, when symptoms of sciatica and spinal stenosis most frequently appear).

During the examination, the patients were asked regularly about pain in the spine or in the legs, especially during compression. If necessary, the pressure could be released immediately by knee flexion. To avoid loading in patients with a vertebral fracture, severe osteoporosis, or tumors, all the patients were examined regularly in the conventional PRP before the ACE.

The CT examinations were performed on a Somatom Plus S unit (Siemens, Erlangen, Germany). Before the CT examination, 3 to 6 mL of iohexol (180 mg/mL) (Omnipaque; Nycomed, Amersham) was injected intrathecally. The CT examination was performed approximately 30 minutes after the contrast injection.

The MRI examinations were conducted on a 1-T system (Magnetom Impact; Siemens) using a surface coil. The patients were examined with sagittal and axial T1- and T2-weighted spin-echo or turbo spin-echo sequences.

All the examinations were performed in PRP followed by ACE. The box for transverse CT and MRI slices was placed parallel to the disc and as equally as possible in each position. The dural sac cross-sectional area (DCSA) was determined using a standard measurement program in the CT or MRI unit.^{4,28} According to experimental and clinical studies by Schönström and Hansson,¹⁹ constriction of the cauda equina, measured as the DCSA, to a size averaging less than 75 mm² affects the normal function of the nerve roots.^{13,24} In every patient, the image selected was that in which the dural sac seemed to have the smallest area on each disc and lateral recess

level. To ensure that the images chosen for measurements in every position were comparable, the radiologist had to compare nerve roots, other soft tissues, and bony structures such as facet joints and the lamina. The radiologist looked carefully for signs that denoted narrowing of the lateral recess and for any compression or flattening of the nerve roots at any level investigated.^{4,28} Any deformation of the dural sac; any suspicion of disc herniation, narrowing of the intervertebral foramen, or ligamentum flavum thickening, and any sign of a possible synovial cyst adjacent to a facet joint were noted.

Criteria for *additional valuable information* (AVI) obtained from the axially loaded examination was defined as 1) a significant reduction of the DCSA (>15 mm²)^{3,28} to areas smaller than 75 mm² (the borderline value for canal stenosis) from PRP to ACE, or 2) a suspected disc herniation, lateral recess or foraminal stenosis, or a intraspinal synovial cyst at PRP changing to obvious manifestation at ACE.

A total of 172 patients (83 females and 89 males) with a mean age of 50 years (range, 14–80 years) were included in the study. From 1993 to 1994, 50 patients were investigated with the described CT myelographic technique. After that time, 122 patients were examined with MRI until the end of the study in April 1998.

The patients were selected for three groups according to their symptoms: low back pain, sciatica, or neurogenic claudication. Consequently, 33 patients were included in the group with low back pain (mean age, 43 years; range, 25–70 years), 84 in the group with sciatica (mean age, 49 years; range, 14–75 years), and 55 in the group with neurogenic claudication (mean age, 58 years; range, 36–80 years). The history of reported problems varied from 0.5 to 10 years in the group with low back pain, from 1 to 15 years in the group with sciatica, and from 0.5 to 20 years in the group with neurogenic claudication.

The methods used in the current study were approved by the ethical committee at the University of Göteborg.

Results

In 50 of the 172 examined patients (29%), AVI was found by the axially loaded CT or MR examinations if the criteria described under the Methods section were followed. However, when the patients with DCSA exceeding 130 mm² in PRP on any disc level were excluded (71 patients), significant additional information was found in 50 of 101 (50%) patients (Table 1A and 1B).

In the group with neurogenic claudication, AVI was found in 38 of 55 (69%) patients. In patients with a DCSA exceeding 130 mm² on all levels were excluded, AVI was found in 38 of 53 (72%) patients (Figures 2 and 3).

Table 1A. Description of the Patients with Neurogenic Claudication, Where Examination in Axially Loaded CT or MR Added Valuable Information (AVI) for Further Treatment Decisions

EM and Pat. No.	Age (Yr)	Gender (M/F)	History of Complaint (Yr)	Neurogenic Claudication m/N	Dural Sac CSA (mm ²) Disc Level				ACE				Foraminal Stenosis	Disc Hern	Leg Pain at ACE	Prev. Surg.	Comment
					L2-3	L3-4	L4-5	L5-S1	Narrow Lateral Recess								
					PRP-ACE	PRP-ACE	PRP-ACE	PRP-ACE	L2/3	L3/4	L4/5	L5/S1					
CT 2	40	M	4	500/t			52-33	35-19			1						
CT 9	47	M	8	-/-			109-69			1	1					1	
CT 10	59	F	2	500/1		78-60	52-39	56-55								1	
CT 32	67	M	5	-/1		94-62	50-50	94-67		1	1						
CT 33	42	F	3	-/-			83-56										
CT 34	42	M	5	300/-		60-33	84-68			1	1		L3, L4				
CT 40	44	F	3	100/1			61-45				1						
MR 1	69	M	1	500/1	96-76	94-97	58-58									1 bi	
MR 2	49	F	2	500/-			78-66			1							
MR 3	59	M	10	500/-		60-60	88-75	67-69						L3 dx		1 dx	
MR 4	65	M	5	500/-			49-52	99-100		1				L4/5 dx			
MR 5	50	F	8	500/-							1			L5/S1		1	
MR 8	71	F	2	100/1		88-82	61-43	84-87		1			L5 dx				
MR 9	47	M	0.5	-/-		106-75	79-48	68-52		1	1			L5/S1	1	1	DH L4/5
MR 12	62	M	10	-/-		122-97	84-61	55-39		1							
MR 13	49	F	4	-/-			148-102	94-63									
MR 14	55	F	2	500/1			88-65				1						
MR 22	49	M	1	-/-				152-124				1					
MR 24	54	M	5	200/1		57-45	64-49			1	1						
MR 29	42	F	0.5	-/-			73-55				1						
MR 34	53	F	1	-/-			79-55				1						
MR 35	63	F	2	500/1		120-92	164-134			1	1						
MR 36	72	M	2	200/1			80-50				1						
MR 37	73	M	2	200/1		100-60	100	90		1SC		1				1	1994 spinal stenosis L3/5
MR 38	71	M	2	500/-		90-60	100-60										
MR 40	71	M	4	500/-	100	90-70	90-60								1 sin	1	Spinal stenosis L3/5
MR 46	83	F	2	-/-	110-80	85-60	100-90										
MR 47	82	F	1	-/1		89-78	69-50				1	1					
MR 49	59	M	1	-/1	80	80	75-50	90			1			DP			
MR 51	57	M	5	500/-			95-70				1						
MR 52	53	F	1	100/1		80-60	95-80										
MR 63	41	M	4	200/-		85-70				1				L3/4 DP			
MR 66	40	M	1.5	200/1			75-60	90									
MR 69	38	F	4	500/1			80-60				1					1	1984 DeFu L5/S1
MR 70	36	M	14	200/1		75-60	80	80								1	St p vertebral fracture L3
MR 90	48	F	5	-/-		80-60	100-80				1	1				1	DH L5/S1
MR 111	69	M	1	-/-						1	1	1		L2/3/4/5			
MR 115	56	M	4	-/-		60-40	100-80				1						

CT = computed tomography; MR = magnetic resonance tomography; m = walking tolerance; - = no information; N = motor/sensory impairment at walking (1 = yes, 0 = no); EM = examination method; PRP = psoas relaxed position; ACE = axial compression in extension; CSA = cross sectional area; sin = left; cen = central; dx = right; bl = bilateral; Narrow lateral recess: **bold 1** = significant narrowing at ACE; Disc herniation: **bold letters** = increasing size at ACE.

Among the patients with sciatica, AVI was found in 12 of 84 (14%) patients. After exclusion of patients with a DCSA exceeding 130 mm² on all levels, AVI was found in 12 of 42 (33%) patients.

If patients without any suspicion of nerve tissue encroachment at PRP were excluded, AVI was found in 12 of 24 (50%) patients. An obvious encroachment of the lateral recess with compression of the nerve root, unilaterally or bilaterally, was recorded during ACE in 35 patients on 42 levels. In one of these patients, an occult synovial cyst not visible during PRP protruded from the facet joint during ACE. This explained the patient's L4 rhizopathy (Figure 4).

In 14 patients, more than one stenotic level was disclosed during ACE. Whereas 19 patients had a disc her-

niation, only four of the herniations had increased in size at ACE.

Altogether, 31 patients had undergone surgery for a spinal disorder before the axially loaded examination. In six of these patients, AVI was elicited during ACE (Table 1 A and B).

The DCSA decreased significantly to less than 100 mm² in 11 patients during ACE. These findings were not registered as AVI. The patients who had low back pain with or without referred pain did not disclose any AVI during ACE. In the 172 examined patients, the highest DCSA value during PRP that significantly decreased to less than 75 mm² during ACE was 100 mm² at L3-L4 (60 mm² during ACE), 109 mm² at L4-L5 (69 mm² during ACE), and 120 mm² at L5-S1 (30 mm² during ACE).

Table 1B. Description of Patients with Sciatica, Where Examination in Axially Loaded CT or MR Added Valuable Information (AVI) for Further Treatment Decisions

EM and Pat. No.	Age (Yr)	Gender (M/F)	History of Complaint (Yr)	Dural sac CSA (mm ²) Disc level				ACE					Foraminal Stenosis	Disc Hern	Leg Pain at ACE	Prev. Surg.	Comment		
				L2-3		L3-4		L4-5		L5-S1		Narrow Lateral Recess							
				PRP-ACE	PRP-ACE	PRP-ACE	PRP-ACE	L2/3	L3/4	L4/5	L5/S1								
CT 1	44	F	1			138-96	88-59												
CT 7	47	M	15			157-98	102-30				1	1			1	1	1963; 1986 Multipel dexompr L4/5, L5/S1		
CT 8	33	M	6				186-99								1				
CT 14	48	F	7				132-86												
CT 16	46	M	4			117-103	92-52				1			L4 sin	1		Psoriasis		
CT 28	48	F	0.5			72-52	94-81							L4 cen + dx	1 sin	1	1988 DH L4/5		
CT 36	43	M	2				94-62	92-95					L4/5						
MR 7	29	M	5				94-57								L5/S1	1			
MR 17	50	M	0.5																
MR 43	65	F	2			80-85													
MR 56	49	F	2				100-90												
MR 76	70	F	2				80-65	98							L4/5 dx				
															L1/2				

EM = examination method; PRP = psoas relaxed position; ACE = axial compression in slight extension; CSA = cross sectional area; sin = left; cen = central; dx = right; bl = bilateral; sin = left; cen = central; dx = right; bl = bilateral; Narrow lateral recess: **bold 1** = significant narrowing at ACE; Disc herniation: **bold letters** = increasing size at ACE.

Discussion

The importance of spinal loading and posture during CT and MR examinations has been reported in experimental and clinical studies by several authors in recent years.^{4,7,12,15,18,21,25-28} Penning and Wilmsink¹⁵ showed in a CT myelographic study of patients with sciatica or neurogenic claudication that the dural sac narrowed concentrically in the spinal canal during extension, and that a widening with relief of involved nerve roots in flexion occurred.

In two *in vitro* studies using a pressure-recording technique, Schönström and Hansson¹⁹ studied the size of the cauda equina. They found that a borderline area averaging $77 \pm 13 \text{ mm}^2$ was needed for the nerve roots at L3-L4. In a previous clinical study of patients with spinal stenosis,² confirmed at surgery, the chosen DCSA was $90 \pm 35 \text{ mm}^2$. The findings led to the conclusion that the space needed for the dural sac at L3-L4 is in the range of 70 to 100 mm^2 .

Willén et al²⁸ and Danielson et al⁴ developed the axially loaded CT myelographic technique, and later the MRI technique, conducted with the subject in a supine position. When they began investigating supine axial loading of the lumbar spine during CT myelographic examinations, eight patients with signs of sciatica or neurogenic claudication also were examined in extension of the lumbar spine without loading. The decrease in DCSA during ACE at 14 disc sites was significantly more pronounced than during supine lumbar extension alone. After that discovery, all examinations have been conducted in PRP and ACE.

The changes in the spinal canal from PRP to simulated upright standing (ACE) were described in two studies.^{4,28} According to these studies, there is a considerable risk of failing to detect an essential narrowing of the spinal canal if the examination is performed only in the

unloaded traditional position. The specificity of the encroachment diagnosis was shown to increase considerably when the patient was subjected to an axial load.

In a study of healthy individuals, Kimura and Hargens⁷ showed that the load comprising 50% of a subject's body weight applied by a compression device can morphologically simulate the lumbar spine in upright position.

In a recent study, nonsymptomatic subjects in different age groups (range, 20-60 years) with no spinal disorders during the lifetime were examined by axially loaded MRI.³ As expected, progressive degenerative signs were found in the functional spinal units correlated with increasing age. No significant narrowing of DCSA to less than 75 mm^2 was registered, except for one at L4-L5 in a 50-year-old man, in whom also the lateral recess on one side was narrowed during ACE. No concurrent symptoms were registered.

In a comparative study of open MRI by Lee,⁸ the effect of upright standing in a kneeling position, as compared with axially loading of the lumbar spine in a supine position, was assessed in healthy subjects. The effects on bulging of the discs, change of the angles between the vertebrae, and change of the lumbar lordosis were equal during the two types of loading. However, the lordosis was more pronounced in the upright position, which might indicate the advantage of inserting a small pillow beneath the lumbar spine during the examination.

Despite continuous development of MRI equipment, including open MRI, essential problems still arise during attempts to perform examinations in upright posture for patients with spinal disorders. Schmid et al¹⁸ presented a study in which healthy individuals were investigated while sitting in an open MRI. These individuals were able to sit motionless during the examination, and it was possible to measure the cross-sectional area of the spinal

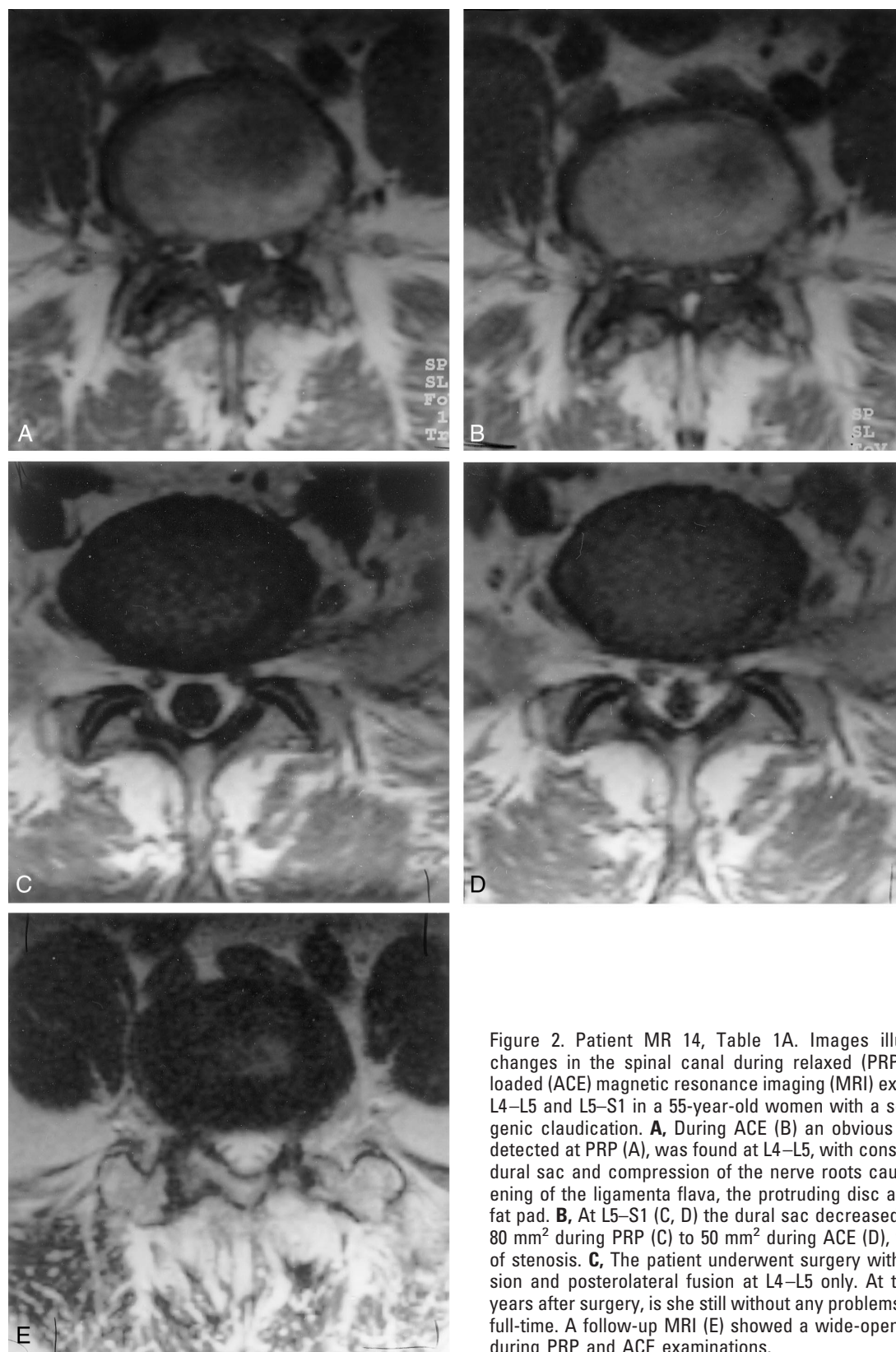


Figure 2. Patient MR 14, Table 1A. Images illustrating the changes in the spinal canal during relaxed (PRP) and axially loaded (ACE) magnetic resonance imaging (MRI) examinations of L4–L5 and L5–S1 in a 55-year-old woman with a serious neurogenic claudication. **A**, During ACE (**B**) an obvious stenosis, not detected at PRP (**A**), was found at L4–L5, with constriction of the dural sac and compression of the nerve roots caused by thickening of the ligamenta flava, the protruding disc and the dorsal fat pad. **B**, At L5–S1 (**C**, **D**) the dural sac decreased in area from 80 mm² during PRP (**C**) to 50 mm² during ACE (**D**), without signs of stenosis. **C**, The patient underwent surgery with decompression and posterolateral fusion at L4–L5 only. At this writing, 6 years after surgery, is she still without any problems and working full-time. A follow-up MRI (**E**) showed a wide-open spinal canal during PRP and ACE examinations.

canal and the foramina as well. This accords with findings by Weishaupt et al,²⁶ who reported on patients with chronic low back pain investigated using the same method. Similar to the findings in the current study, no

convincing signs of canal or foraminal encroachments were found.

In a study by Wildermuth et al,²⁷ patients with combined low back pain and sciatica, also examined while

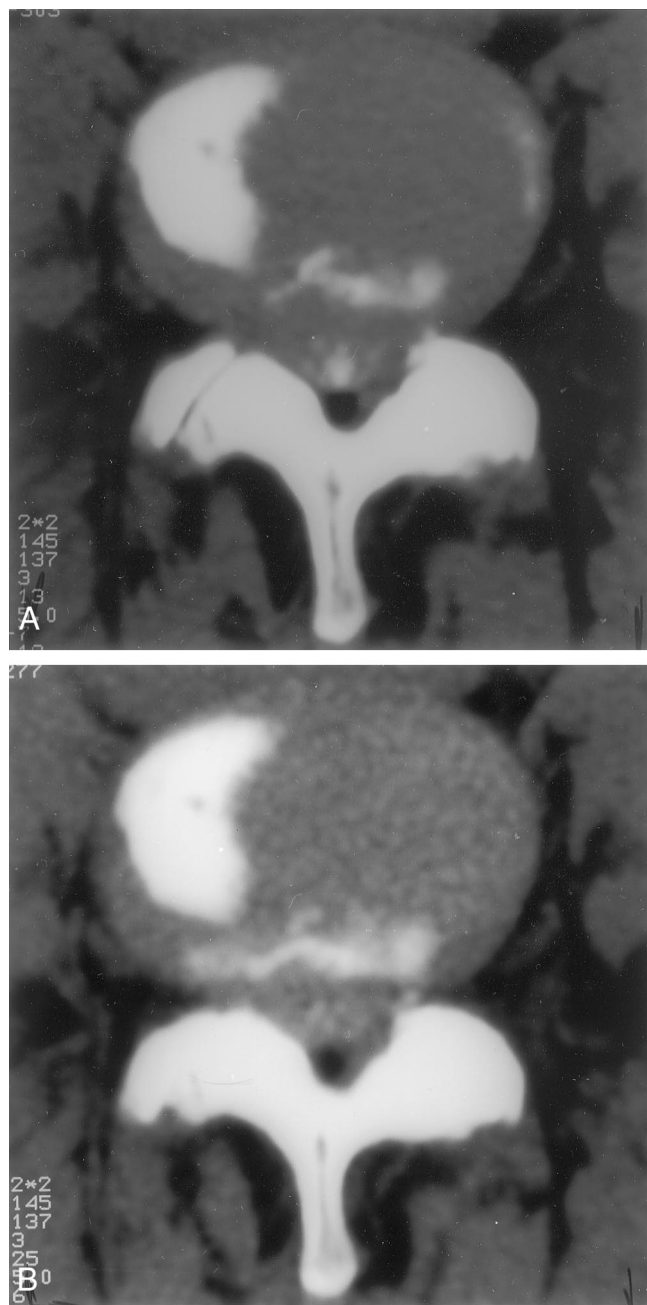


Figure 3. Patient 40. Computed tomography (CT) myelographic images of L4–L5 in a 44-year-old woman with a 1-year history of pain and impaired motor and sensory function in her legs when walking less than 100 m. The cross-sectional area of the dural sac in disc level decreased significantly to an indisputable stenosis from (A) relaxed position (PRP) to (B) axially loaded position (ACE). After decompression and fusion, her leg pain disappeared, and at this writing, she has been back at work full-time for 3 years.

sitting in an open MRI, the overall examination time created severe pain problems. Motion artifacts and difficulties in reproducing the positioning between the sequences occurred regularly. This impaired the possibilities for analyzing the content of the spinal canal.

Moreover, in the sitting position the psoas muscles are relaxed, which tends to provoke the lumbar spine into flexion. Conversely, in standing, the psoas muscles are

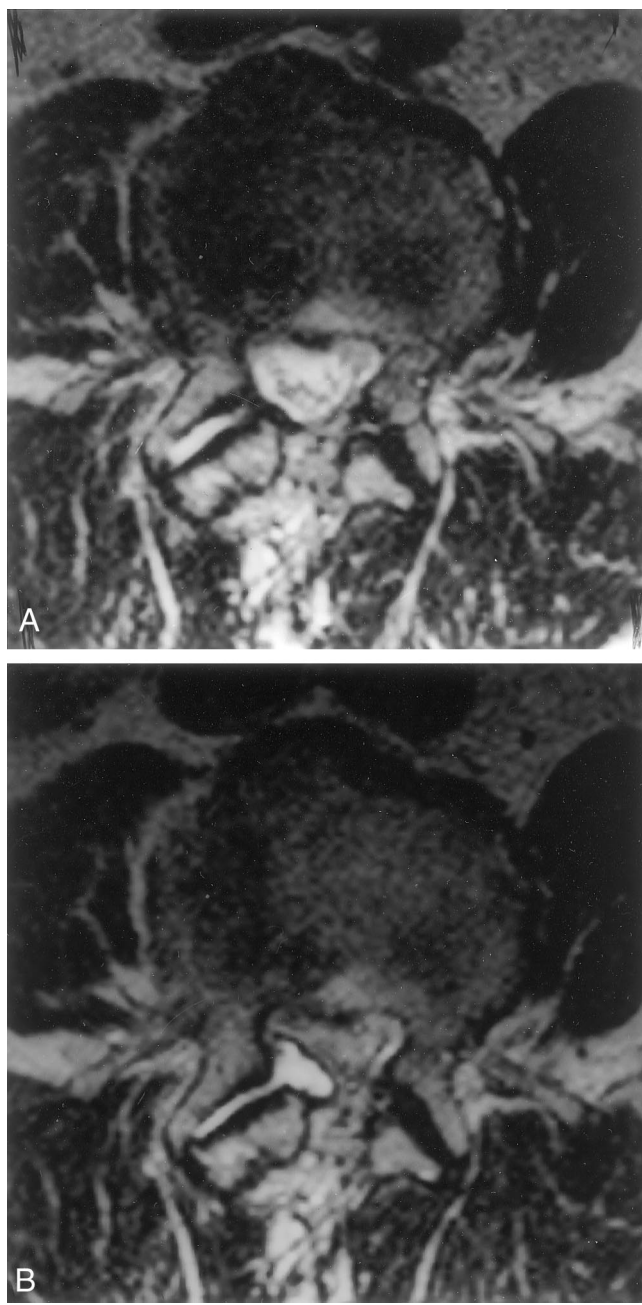


Figure 4. Patient MR 37. Magnetic resonance images (MRI) of L3–L4 in a 77-year-old man who underwent surgery for a spinal stenosis at L3–L5 with decompression 4 years before the current examination. He was pain free for 2 years, but since then has experienced an intractable L4 rhizopathy in his right leg. Results from MRI examination during PRP (A) were normal, whereas examination during ACE (B) showed a large synovial cyst protruding from the right L3–L4 facet joint and affecting the L4 nerve root.

stretched, which increases the lordosis and tends to decrease the space in the spinal canal.

The advantages of the so-called kinematic but unloaded MRI, as compared with the conventional, relaxed position of the cervical spine was described by Muhle et al⁹ in examinations of patients with disc disease, spondylosis, radiculopathy, and myelopathy. The AVI obtained by the kinematic MRI, in which the cervical spine

is moved from flexion to extension, was correlated with the clinical symptoms. In 21 of 26 patients the AVI obtained by kinematic MRI imaging influenced the therapeutic management and intraoperative positioning.

The reported findings of Muhle et al⁹ reflects the experience of the current authors with axially loaded examinations of the lumbar spine in the supine position. In the current study, the AVI during axially loaded examination of the lumbar spine was correlated with the clinical symptoms and signs.

When the results of the examination were judged without use of the recommended inclusion criteria, AVI during ACE was found in 50 of 172 study patients (29%). Of the 55 patients with signs of neurogenic claudication, AVI was found in 36 (69%).

In patients with sciatica, AVI was found only in 14% if the inclusion criteria for the ACE were not used. The inclusion criteria, described in the basic studies by Willén et al²⁸ and Danielson et al,⁴ comprised a DCSA smaller than 130 mm² at all disc levels, a suspected narrow lateral canal with or without deformation of the anterolateral part of the dural sac, or a suspected nerve root compression during PRP. When these indications for examination in ACE were added, the AVI was increased from 14% to 50% in the group with sciatica group, but only from 69% to 72% in the group with neurogenic claudication. No AVI was found in the group with low back pain. This indicates the need to evaluate the history of each patient's reported problems before deciding to perform an examination in ACE.

The additional diagnostic effect of axially loaded examinations is generally high in patients with obvious clinical signs of any encroachment into the spinal canal. In clinical practice, it is essential to avoid examinations of patients without signs of sciatica or neurogenic claudication.

The recommendation that a DCSA value of 130 mm² should be used as an inclusion criteria for examination during ACE was based on previous experimental¹⁹ and clinical studies.^{2,4,28} According to the current analysis of the 172 patients, the PRP value of 130 mm² might be too high. The highest value of DCSA during examination in PRP that reached values below 75 mm² at examination in ACE was 100 mm² at L3–L4, 109 mm² at L4–L5, and 120 mm² at L5–S1. As an inclusion criterion, it might be reasonable to decrease the borderline PRP value to 110 mm² for at least levels at or above L4–L5. It is crucial to remember that the probability of finding useful information for treatment decreases with a too liberal attitude toward performing examinations during ACE.

Several experimental studies support the opinion that double-level stenosis impairs local nerve blood flow and nerve impulse propagation.^{5,6,13,24} In a CT myelographic study of patients with neurogenic claudication, Porter and Ward¹⁶ showed that this disorder often is associated with stenosis at least on two disc sites. At the different levels, there might be a combined central, lateral, or foraminal stenosis. In an experimental study on a human section material using CT and MR examinations,

Nowicki et al¹² showed that at some levels there were impressive decreases in the foraminal space from flexion to extension, and even to other positions. Therefore, it must be emphasized that a severe stenosis at one location should not exclude further attempts to investigate other disc sites where suspected changes might give rise to a stenotic situation in a certain body position.

■ Conclusion

Experience with axially loaded CT and MRI examination of the lumbar spine indicates that the risk of failing to detect an essential spinal canal stenosis is considerable if only the examination using the traditional psoas relaxed position is performed. However, it is necessary to select the patients for the procedure after serious evaluation of their history of problems and the objective clinical and radiologic signs. According to the current results, the axially loaded examination should always be performed after the conventional examination to optimize the radiologic diagnosis in patients with signs of neurogenic claudication. In patients with sciatica, examination is indicated for those with suspected narrowing of the spinal canal or foramina, and those with a dural sac cross-sectional area smaller than 130 mm² at or above L4–L5. However, no measurable guidelines have been established for L5–S1, partly because of the dural sac's tapered configuration at that level.

Every MRI examination of a patient with a suspected encroachment into the lumbar spinal canal should start with a conventional investigation using PRP to avoid loading of an osteoporotic or fractured spine or a spine with a skeletal malignancy representing contraindications for loading. Examination in extension alone will improve the diagnostic specificity to a certain extent and might be used in elderly people or patients with clinical signs of osteoporosis.

In patients who have low back pain with or without referred pain to the legs, and without any suspicion of narrowing of the spinal canal during PRP examination, the probability of finding a pathology that explains their pain during ACE examination is very low.

■ Key Points

- It is well documented that a narrowing of the lumbar spinal canal is provoked in axial loading combined with extension of the spine.
- Consequently, CT scan and MRI still are performed with the patient in a supine relaxed position, resulting in unloading of the spine and enlargement of the canal.
- The risk of failing to detect an essential stenosis is thus considerable.
- According to the current study, an axially loaded CT or MRI examination should always be performed after the conventional examination in patients with signs of neurologic claudication and in selected patients with sciatica to optimize the radiologic diagnosis.

Acknowledgments

The authors thank the staff at the Department of Magnetic Resonance Imaging at Mölndal Hospital for performing the study examinations, and Jill Fallenius and Karin Lindborg for secretarial assistance.

References

- Amundsen T, Weber H, Lilleås F, et al. Lumbar spinal stenosis: Clinical and radiological features. *Spine* 1995;20:1178–86.
- Bolender NF, Schönström NS, Spengler DM. Role of computed tomography and myelography in the diagnosis of central spinal stenosis. *J Bone Joint Surg [Am]* 1985;67:240–6.
- Danielson BI, Willén J. Axial loading in MRI of the lumbar spine in asymptomatic individuals. *Spine* 2001;26:2601–2606.
- Danielson BI, Willén J, Gaultz A, et al. Axial loading of the spine during CT and MR in patients with suspected spinal stenosis. *Acta Radiol* 1998;39:604–11.
- Hamanishi C, Matukura N, Fujita M, et al. Cross-sectional area of the stenotic lumbar dural tube measured from the transverse views of magnetic resonance imaging. *J Spinal Disord* 1994;7:388–93.
- Jespersen S, Hansen E, Hoy K, et al. Two-level spinal stenosis in minipigs: Hemodynamic effects of exercise. *Spine* 1995;20:2765–73.
- Kimura S, Hargens A. Lumbar spinal disc height and curvature responds to an axial load using a MRI-compatible compression device. *Spine* 2001;26:2596–2600.
- Lee SU. Comparison of upright MRI of the lumbar spine with supine MRI using a spinal compression harness. Personal communication, 2000.
- Muhle C, Metzner J, Weinert D, et al. Kinematic MR imaging in surgical management of cervical disc disease, spondylosis, and spondylytic myelopathy. *Acta Radiologica* 1999;40:146–53.
- Muhle C, Wiskirchen J, Weinert D, et al. Biomechanical aspects of the subarachnoid space and cervical cord in healthy individuals examined with kinematic magnetic resonance imaging. *Spine* 1998;23:556–67.
- Nachemson A, Elfström G. Intravital dynamic pressure measurements in lumbar discs. A study on common movements, maneuvers and exercises. *Scand J Rehabil Med Suppl* 1970;1:1–40.
- Nowicki BH, Houghton VM, Schmidt TA, et al. Occult lumbar lateral spinal stenosis in neural foramina subjected to physiologic loading. *Am J Neuro-radiol* 1996;17:1605–14.
- Olmarker K. Spinal nerve root compression: nutrition and function of the porcine cauda equina compressed *in vivo* [review]. *Acta Orthop Scand Suppl* 1991;242:1–27.
- Penning L, Wilmink JT. Biomechanics of the lumbosacral dural sac: a study of flexion–extension myelography. *Spine* 1981;6:398–408.
- Penning L, Wilmink JT. Posture-dependent bilateral compression of L4 and L5 nerve roots in facet hypertrophy: a dynamic CT-myelographic study. *Spine* 1987;12:488–500.
- Porter R, Ward D. Cauda equina dysfunction: the significance of two-level pathology. *Spine* 1992;17:9–15.
- Sato K, Kikuchi S, Yonesawa T. *In vivo* intradiscal pressure measurement in healthy individuals and in patients with ongoing back problems. *Spine* 1999;24:2468–74.
- Schmid MR, Stucki G, Duetwell S, et al. Changes in cross-sectional measurements of the spinal canal and intervertebral foramina as a function of body position: *in vivo* studies on an open-configuration MR system. *AJR Am J Roentgenol* 1999;172:1095–102.
- Schönström NSR, Hansson T. Pressure changes following constriction of the cauda equina: an experimental study *in situ*. *Spine* 1988;13:385–8.
- Schönström NSR, Lindahl S, Willén J, et al. Dynamic changes in the dimensions of the lumbar spinal canal: an experimental study *in vitro*. *J Orthop Res* 1989;7:115–21.
- Schönström NSR, Willén J. Imaging lumbar spinal stenosis. *Radiol Clin North Am* 2001;39:31–53.
- Schumacher M. Die Belastungsmyelographie. *Fortschr Röntgenstr* 1986;145:642–8.
- Sortland O, Magnaes B, Hauge T. Functional myelography with metrizamide in the diagnosis of lumbar spinal stenosis. *Acta Radiol Suppl* 1977;355:42–54.
- Takahashi K, Olmarker K, Holm S, et al. Double-level cauda equina compression: an experimental study with continuous monitoring of intraneural blood flow in the porcine cauda equina. *J Orthop Res* 1993;11:104–9.
- Tallroth K, Lindgren KA, Willén J. Axial Loading of the Lumbar Spine in CT Scanning: A Valuable Complement in the Diagnosis of Central Spinal Stenosis. Poster at the Nordic Orthopaedic Federation, Tampere, Finland, June 2000.
- Weishaupt D, Schmid MR, et al. Positional MR imaging of the lumbar spine: does it demonstrate nerve root compromise not visible at conventional MR imaging? *Radiology* 2000;215:247–53.
- Wildermuth S, Zanetti M, Duetwell S, et al. Lumbar spine: quantitative assessment of positional (upright flexion and extension) MR imaging and myelography. *Radiology* 1998;207:391–8.
- Willén J, Danielson B, Gaultz A, et al. Dynamic effects on the lumbar spinal canal: axially loaded CT myelography and MRI in patients with sciatica and/or neurogenic claudication. *Spine* 1997;22:2968–76.

Address reprint requests to

Jan Willén, MD, PhD
 Department of Orthopaedics
 Sahlgrenska University Hospital
 SE 413 45 Göteborg
 Sweden
 E-mail: jwillen@algonet.se